

## Cheiloscopy: A New Aid for Sex Identification in Forensic Science

N. Chaitanya Babu\*

Premalatha. B. R\*\*

Jude. J\*\*\*

### ABSTRACT

The aim of this study is to ascertain whether lip prints behold the potential for sex identification. Study sample included 40 males and 40 females whose lip prints were recorded with help of lip stick. Lip prints were classified into 4 types based on Tsuchihashi classification for sex identification. If type I and II patterns were present, they were classified as females. If type III and IV patterns were present, they were classified as males. Out of 40 males, 34 were correctly identified as males and out of 40 females, 33 were correctly identified as females. If the sex of the person who committed the crime is known, it is easy to shortlist the suspects. Although determining sex with lip prints is not an accurate method, it can be useful as a supplementary method.

**Keywords:** Cheiloscopy, Lip prints, Sex identification

### INTRODUCTION

Personal identification is one of the most challenging processes confronted by mankind. Finger prints has been successful in field of forensic science to identify individuals for both civil and criminal purposes. Theory of uniqueness is the scientific principle behind finger print analysis to convince the court of law. Likewise, studies done so far show that even lip prints are unique for an individual and hence have the potential for personal identification<sup>(1)</sup>.

The wrinkles and grooves on labial mucosa are called as Sulci labiorum. They form a characteristic pattern in each individual called Lip prints and study of these lip prints are referred to as Cheiloscopy.

Fischer was the first anthropologist to describe the furrows on the red part of the

human lips in 1902. The use of lip prints for personal identification was first recommended by French criminologist Edmond Locard in 1932.

Lip prints are left in the scene of crime either as visible or latent forms. Visible lip prints can be seen with naked eye are produced by lipsticks, lip balms etc when they come in contact with any surface such as cigarette butts, clothes, drinking glasses etc<sup>(2)</sup>. Recently, lip sticks which do not leave any visible trace have been developed. But, these prints can be lifted with the help of materials such as aluminum or magnetic powder<sup>(3)</sup>.

Latent++ lip prints are produced by secretions of sebaceous and sweat glands present in the edges of lips<sup>(4)</sup>. These latent lip prints can be lifted using aluminum, graphite or magnetic powder. Chemicals such as Sudan black, Nile red, Ninhydrin and Iodine can also be used to lift these latent lip prints.

### AIM

The aim of this study is to ascertain whether sex of an individual can be determined with help of lip prints.

**Author's Affiliation:** \*Professor and Head, \*\*Senior Lecturer, \*\*\*Post Graduate student, Department of Oral Pathology, M. S. Ramaiah Dental College, Bangalore, Karnataka, India - 560054.

**Reprint's request:** Dr. N. Chaitanya Babu, Professor and Head, Department of Oral Pathology, M. S. Ramaiah Dental College, Bangalore, Karnataka, India - 560054., E-mail: nischay\_chaitanya@yahoo.co.in,


(Received on 26.09.2010, accepted on 23.10.2010)

**MATERIALS AND METHOD****STUDY MATERIALS****STUDY SAMPLE**

A sample of 80 individuals comprising of 40 males and females aged 17-40 years were included in the study. Individuals with any lesions on the lips and known hypersensitivity to lipsticks were excluded from the study. Consent was obtained from all the individuals for the study.

Materials used were: 1. Dark colored lipstick, 2. Cellophane tape, 3. White chart paper, 4. Magnifying lens, 5. Brush to apply lipstick

**Figure 1**

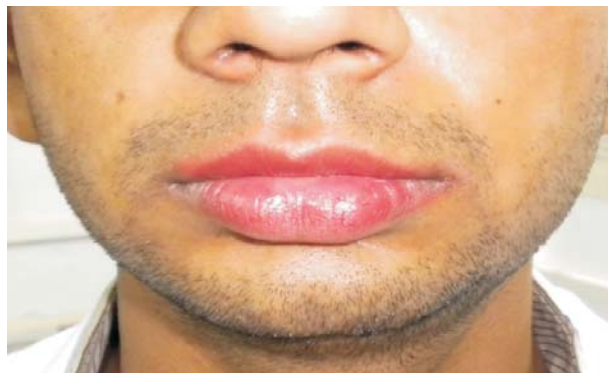

**TECHNIQUE**

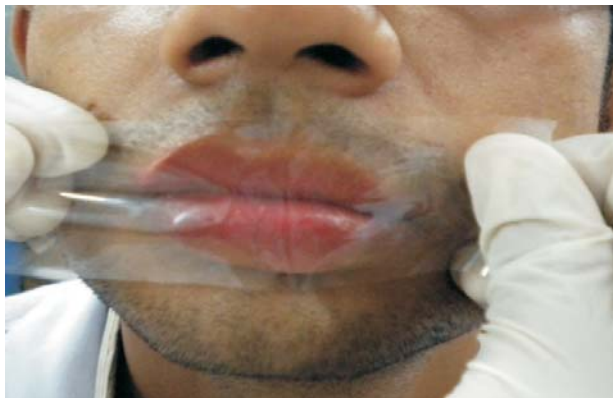The lips of the individuals were cleaned and lipstick was applied evenly on the lips (Fig 2). The subjects were asked to rub their lips to spread the lipstick and moisten. A lip impression was made on glued side of cellophane tape by pressing it slightly over the lips (Fig 3). The

cellophane strip was then struck on a white chart paper for permanent record. Lip prints were coded, i.e. chart paper having lip prints contains just serial numbers. The name and sex of the individuals were entered separately with the serial numbers. Thus at the time of analysis, sex of the lip prints was not disclosed to examiner. Lip prints were then visualized with help of magnifying lens.

**Figure 2.a**



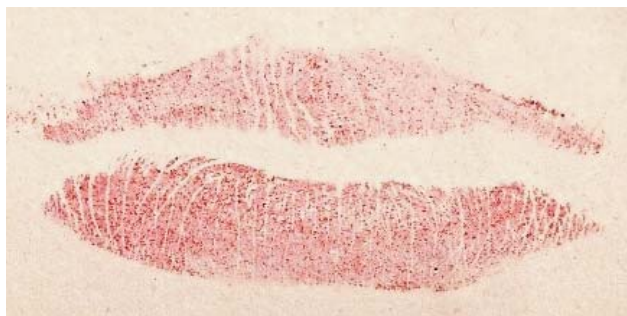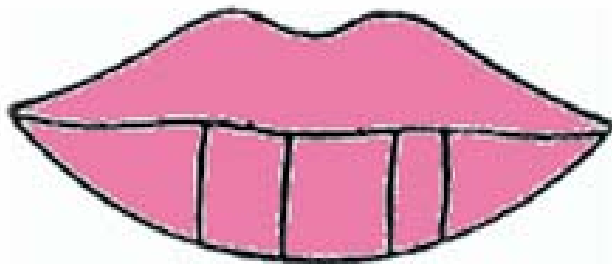
**Figure 2.b**



In this study, lip prints classification method proposed by Tsuchihashi Y<sup>(5)</sup> was followed.

Type I: Clear cut vertical grooves that run across the entire lip

**Figure 3.a**



Type I': Vertical grooves that do not cover the entire lip

**Figure 3. b**

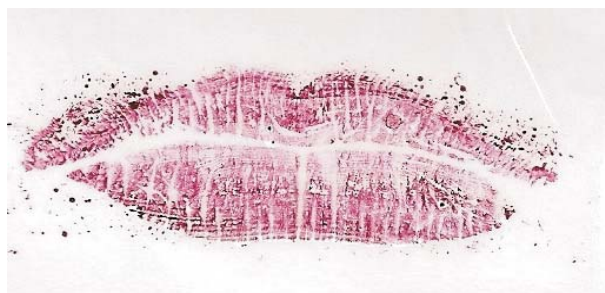
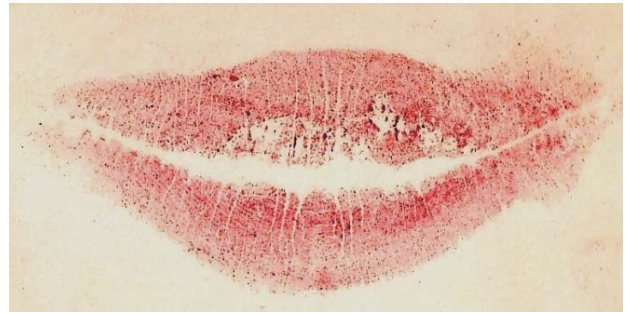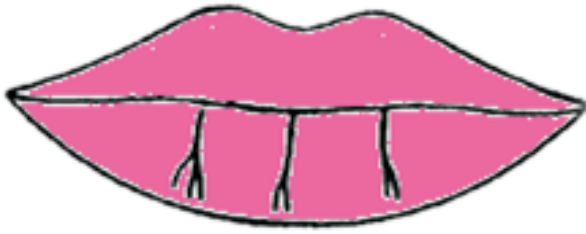

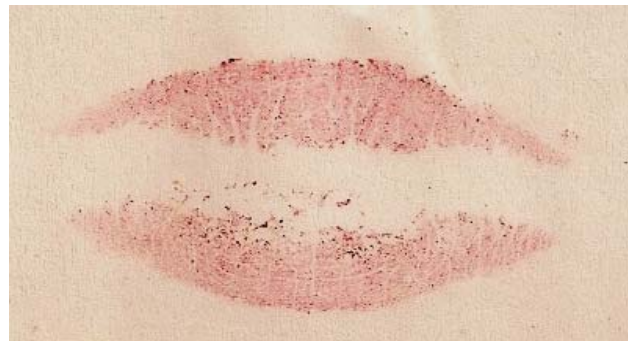
Fig 3.c



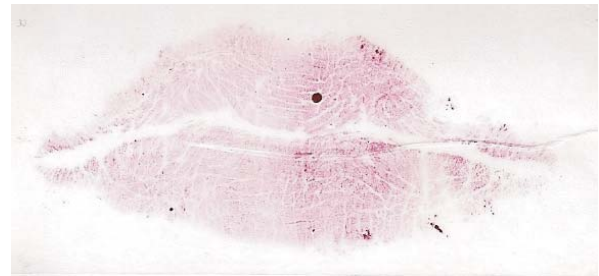
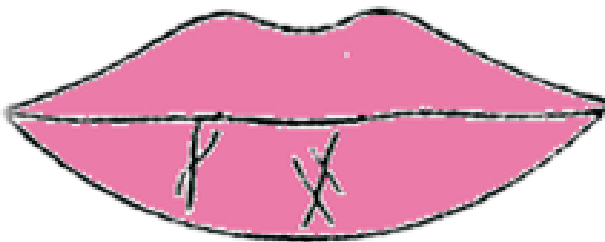
Type III: Criss-cross or reticular grooves

Figure 3.d



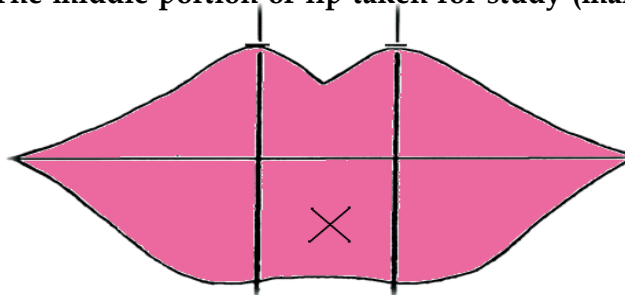
Type IV: Undetermined. (Any other pattern that doesn't fall under above said categories)

Figure 3.e



The middle part of the lower lip (approximately 10mm wide) was taken as study area for classification as proposed by Sivapathasundaram et al<sup>(1)</sup> (Fig 14). This area is selected for study because this part was almost always visible in any trace and was most consistent in subsequent impressions.

Fig 4 : The middle portion of lip taken for study (marked as X)



### Hypothesis

The sex of the individual was determined as:  
(according to Sharma et al) <sup>(6)</sup>

If type I and II patterns are dominant: Female

If type III and IV patterns are dominant: Male

### RESULTS

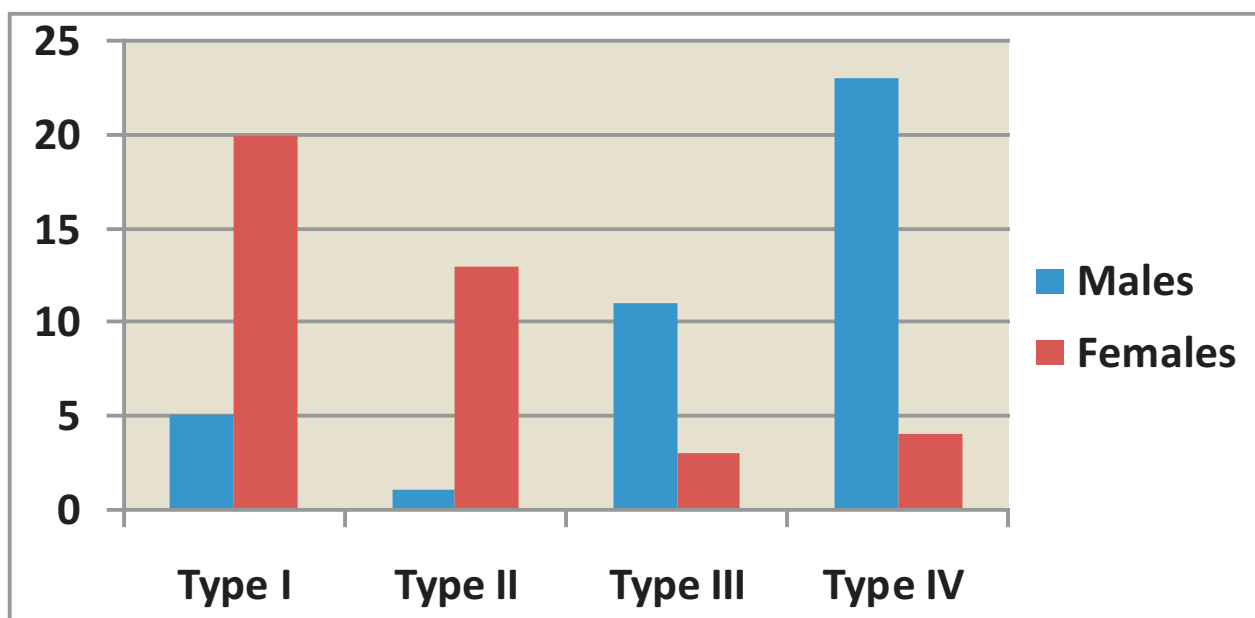
In our study of lip prints of 40 males and 40 females, we found following observations:

1. None of the lip prints matched with each other, thus confirming the uniqueness of lip prints.

2. According to the hypothesis taken, 34/40 males and 33/40 females were correctly identified as males and females. Hence, the accuracy rate was 67/80 (83.75%)

3. When lip prints in males and females were observed, type I and II patterns was

**Figure 5: Distribution of lip prints among males and females according to four types**



**Table I: Distribution of lipprints among males and females in the study**

	Males	Females
<i>Type I</i>	5	20
<i>Type II</i>	1	13
<i>Type III</i>	11	3
<i>Type IV</i>	23	4

Type I and II patterns seen more in females and type III and IV patterns seen predominantly in males

predominant in females and type III and IV patterns was predominant in males.

### REVIEW OF LITERATURE

Suzuki and Tsuchihashi in 1970 examined lip prints in 280 individuals aged 6-57 years and in 18 pairs of twins in Japanese population. They concluded that none of the lip prints were similar to each other<sup>(7)</sup>.

Again in 1974, Tsuchihashi conducted a study in 1364 subjects of 3-60 years old and 49 pairs of uniovular twins to prove that none of the lip prints were identical to each other. Also, he examined 3 males and 4 females at regular monthly intervals for a period of 3 years and proved that lip prints remain unchanged over time<sup>(5)</sup>.

A study was done by Utsuno et al in 6 cadavers before and after 48 hrs from fixation with 10% formalin. He concluded that lip prints remained unchanged and is not affected by fixation<sup>(8)</sup>.

A few studies has been done in past to prove that sex can be identified from lip prints. In a study done by Sonal-Nayak et al, all 30 females were correctly identified as females and 17/20 males were correctly identified as males. Thus accuracy rate of 96-100% was achieved<sup>(9)</sup>.

According to a study done by Preeti-Susmita et al, 18/20 females and 17/20 males were correctly identified as females and males. They got an accuracy rate of around 90 %<sup>(6)</sup>. In another study conducted by Vahanwala-Parekh et al, lip is divided into 4 quadrants and they found that, all quadrants with same type of pattern is found predominantly in females, whereas males showed presence of different patterns in all quadrants<sup>(10)</sup>.

Lip prints also have some disadvantages. The mucosa on the lip is thin; hence changes in lip patterns can result because of pressure variability. Also, changes in lip position when taking lip prints can lead to faulty patterns. Nevertheless, lip prints seem to have distinct advantage of identifying sex over finger prints which can be helpful in investigation.

### DISCUSSION

In our study, we could identify the sex of 34/40 males and 33/40 females correctly and hence got an accuracy rate of around 84%. Accuracy rate of our study is consistent with few studies done previously<sup>(6,9)</sup>. Type I pattern was found in 5 males and 20 females. Type II pattern was found in 1 male and 13 females. Type III pattern was found in 11 males and 3 females. Type IV pattern was found in 23 males and 4 females (Table 1). Type I pattern was found to be predominant in females (50%) and type IV pattern was found to be predominant in males (57.5%) which are same as study done by Sharma-Saxena et al<sup>(6)</sup>. In our study, pattern which is predominant in the middle part of lip is taken into consideration making it easy to classify, even if whole lip print is not available.

### CONCLUSION

Along with finger prints and other evidences, lip prints are clues to look out for in the field of crime, to help investigators to arrive at a correct conclusion at the earliest. Although, determining sex with help of lip prints is not proved to be a 100 % accurate method, it can be used as a supplementary method to get us one step closer to the truth.

### ACKNOWLEDGEMENTS

We would like to thank Dr. Andrea Gomes, Dr. Sindura Rajesh, Dr. Saurabh Juneja and Dr. Vaishali Hotkar for helping in conducting the study.

### REFERENCES

1. Sivapathasundharam B, Prakash PA, Sivakumar G. Lipprints (cheiloscopy). *Indian J Dent Res.* 2001; 12: 24-7.
2. Castello A, Segui AM, Verdu F. Luminous lip prints as criminal evidence. *Forensic Sci Int* 2005; 155: 185-7.
3. Segui MA, Feucht MM, Ponce AC, Pascual FAV. Persistent lipsticks and their prints: New

- hidden evidence at the crime scene. *Forensic Sci Int.* 2000; 112: 41-7.
4. Ball J. The current status of lipprints and their use for identification. *J Forensic Odontostomatol.* 2002; 20: 43-6.
  5. Tsuchihashi Y. Studies on personal identification by means of lipprint. *Forensic Sci Int.* 1974; 3: 233-48.
  6. Sharma P, Saxena S, Rathod V. Cheiloscopy: The study of lipprints in sex identification. *J Forensic Dent Sci.* 2009; 1(1): 24-7.
  7. Suzuki K, Tsuchihashi Y. Personal identification by means of lipprint. *J of Forensic medicine.* 1970; 17(2): 52-57.
  8. Utsuno H, Kanoh T, Tadokoro O, Inoue K. Preliminary Study of post mortem identification using lip prints. *Forensic Sci Int.* 2005; 149: 129-32.
  9. Vahanwala S, Nayak CD, Pagare SS. Study of lipprints as aid for sex determination. *Medico-legal Update.* 2005; 5: 93-8.
  10. Vahanwahal SP, Parekh DK. Study of lipprints as an aid to forensic methodology. *J Indian Dent Assoc.* 2000; 71: 269-71.
-